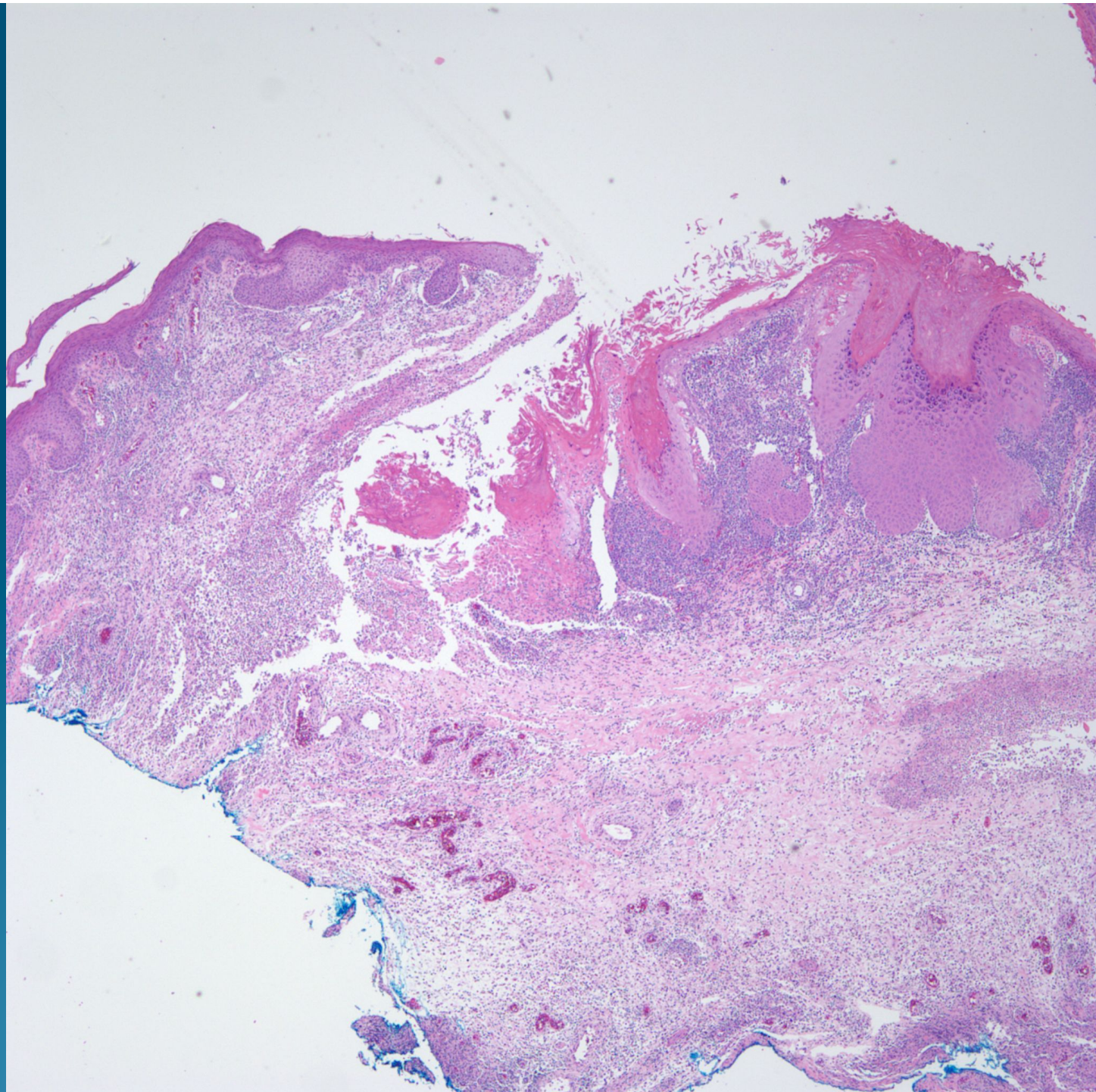
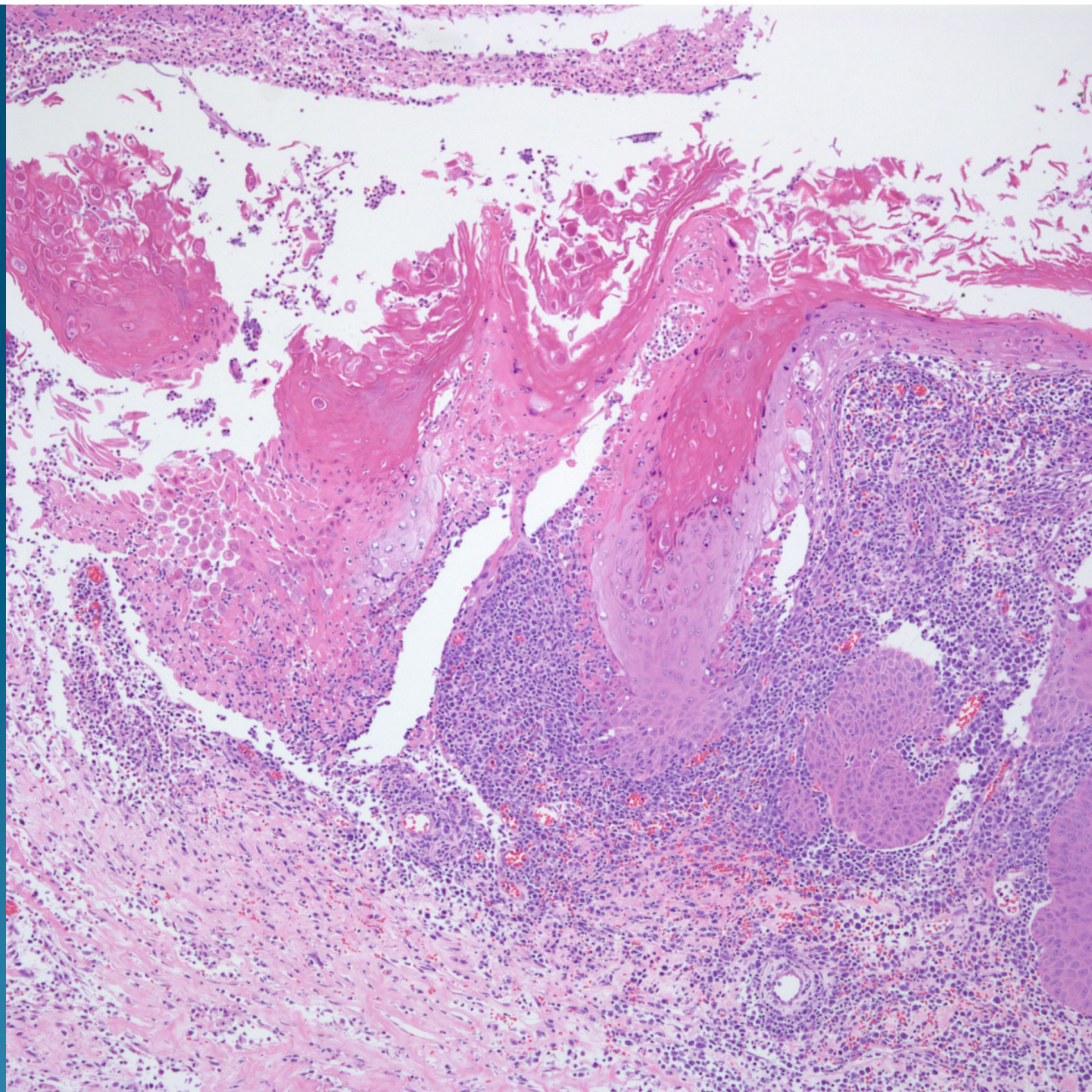
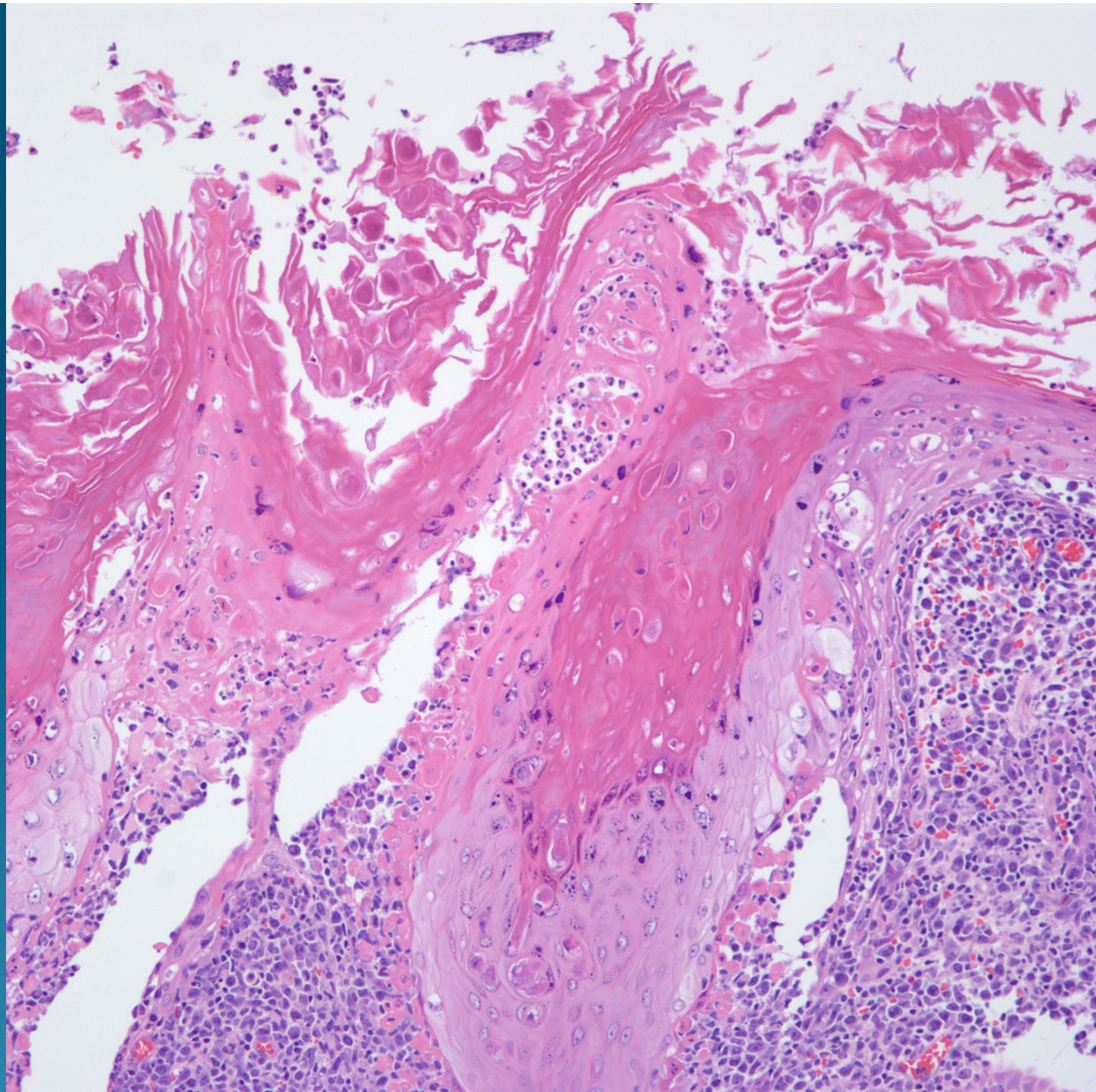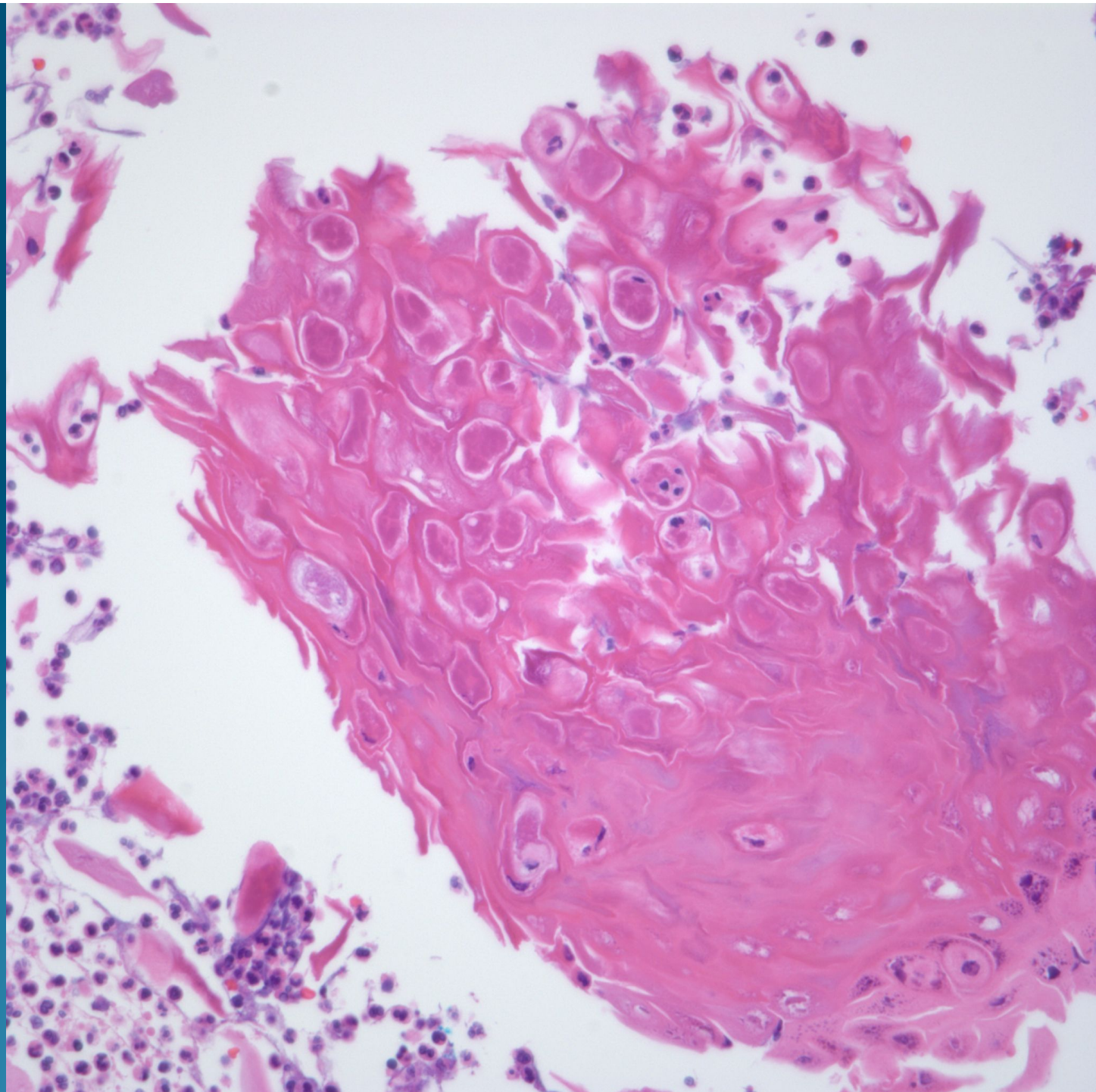# What is the best diagnosis?

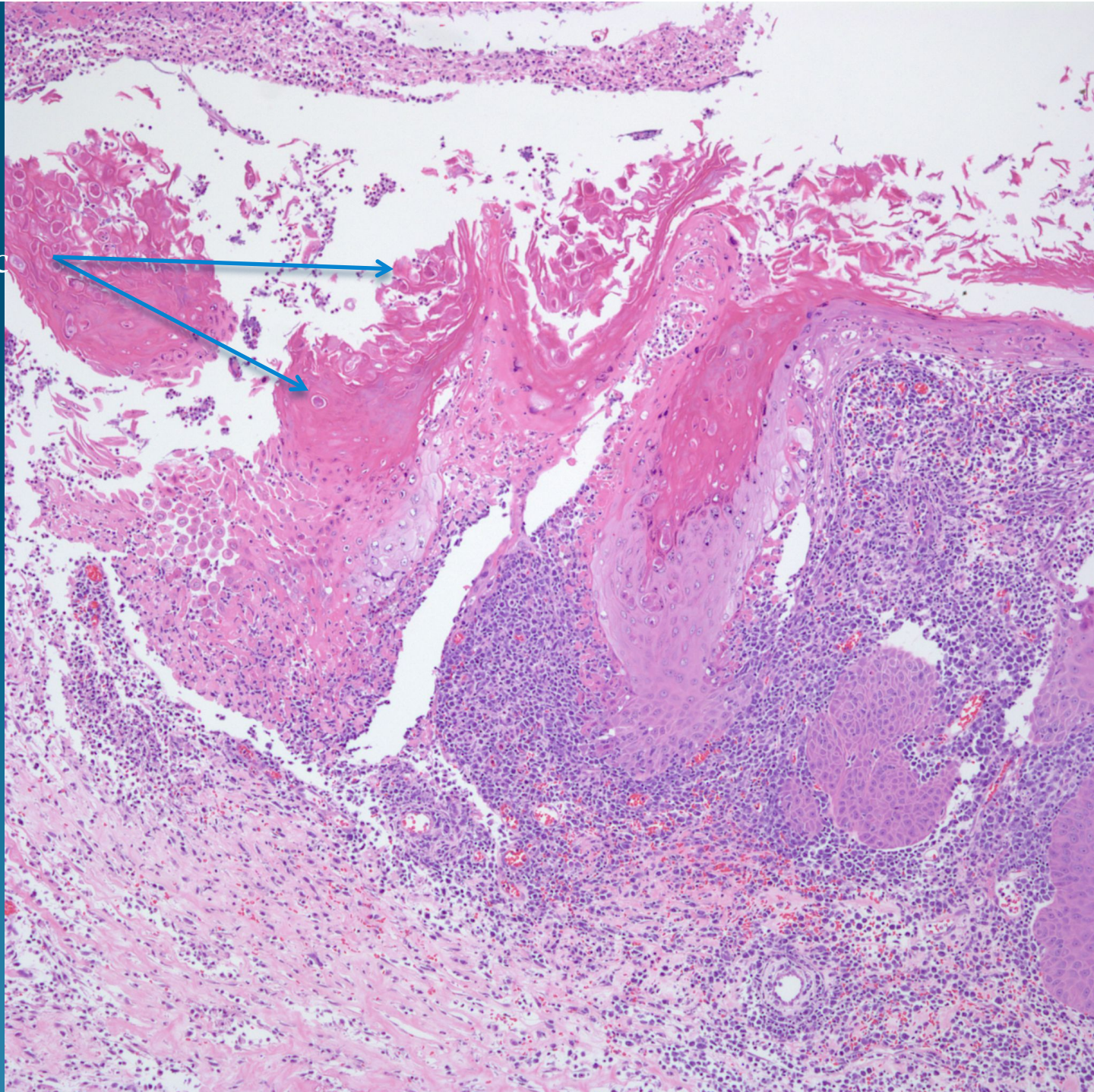
- A. Molluscum contagiosum
- B. Myrmecia
- C. Orf
- D. Herpes simplex virus
- E. Cytomegalovirus

Molluscum contagiosum, inflamed

# Notes

- In some cases of molluscum contagiosum, there is an intense inflammatory response which may obscure the characteristic viral cytopathic changes
- The inflammation may vary from acute and chronic inflammation to granulomas
- Multiple deeper levels may be needed to identify the characteristic viral cytopathic changes

Viral  
Cytopathic  
changes



Increased  
Acute  
And  
Chronic  
Inflamma  
tion